

## **TALAR DOME INJURY**

The dome of the talus articulates with the tibia and fibula, and has a key role in ankle motion and in supporting the axial load during weight bearing.

The talus is the tallest bone in the foot. It is also one of the bones that makes up the ankle joint. The upper part of the talus is called the talar dome. The dome is made up of bone (osteo) that is covered by a layer of articular cartilage (chondral). Articular cartilage is a smooth shiny material that allows the ankle bones to slide easily over each other as the ankle moves. When a part of the dome cracks or breaks off, it is referred to as an osteochondral fracture of the talar dome. These fractures usually occur as a result of an ankle injury or an ankle sprain.

Fractures of the talar dome are generally the result of inversion injuries of the ankle. They are located medially or laterally with equal frequency and occasionally through both. Lateral talar dome fractures are almost always associated with trauma, while medial talar dome lesions can be traumatic or atraumatic in origin. Although the etiology in atraumatic lesions is unclear, osteochondral fragments can separate from the surrounding cartilage surface and dissect into the joint space. As these osteochondral fragments become loose in the joint, they can cause pain, locking, crepitation, and swelling.

### **DIAGNOSIS**

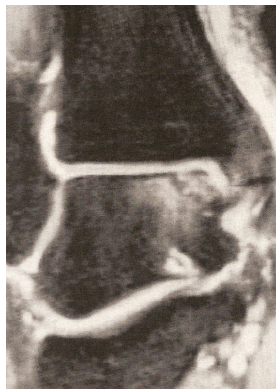Clinical diagnosis of talar dome fractures can be highly challenging and are often missed. The patient may have sustained a fall or a twisting injury to the ankle and may generally ambulate with a limp. In the acute setting, the symptoms of a talar dome fracture are similar to and often occur with an ankle sprain.

In lateral talar dome lesions, tenderness is generally found anterior to the lateral malleoli, along the anterior lateral border of the talus. In medial talar dome lesions, tenderness is usually located posterior to the medial malleolus, along the posterior medial border of the talar dome.

Chronic talar dome lesions, traumatic and atraumatic osteochondritis dissecans lesions may have a clinical presentation similar to that of arthritis. Typical findings include crepitation, stiffness, and recurrent swelling with activity.

Diagnosis of talar dome lesions can often be made with standard anteroposterior (AP), lateral, and mortise ankle radiographs. However, repeated radiographs may be necessary because initial films may appear normal. Secondary changes in the subchondral bone (visible on plain radiographs) caused by a compression fracture of the articular osteochondral surface may take weeks to appear. In addition, small chondral fragments are radiolucent and not evident on standard radiographs.

Generally, the AP ankle view is best for visualizing deep, cup-shaped medial lesions, although the lesions are often appreciated on the mortise view as well. Lateral lesions are best visualized on a mortise view and are generally thin and wafer-shaped. If suggested by the clinical scenario, fractures not visualized with plain radiographs may require magnetic resonance imaging (MRI) or computed tomography (CT).



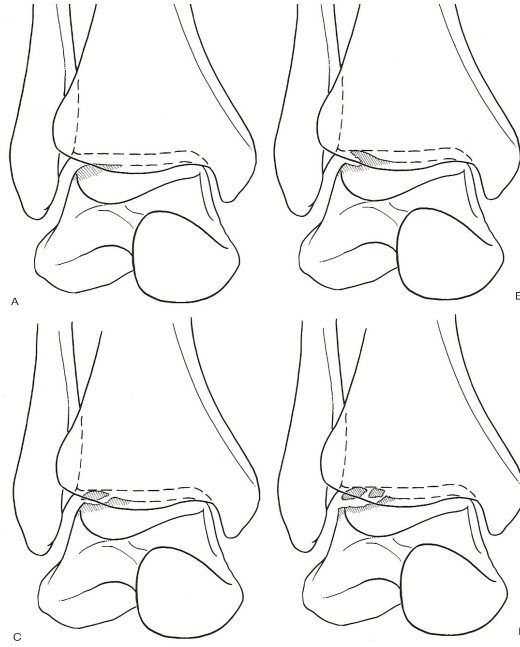
*MRI demonstrates talar dome fracture*

## Classifying Talar Dome Injuries

Talar dome lesions occur in 6.8 to 22.0 percent of ankle sprains, but they can be missed during the initial assessment. The fracture classification developed by Berndt and Harty is widely used to stage talar dome lesions.

### Classification (Berndt and Harty)

Stage I (A):	Subchondral bone compression fracture
Stage II (B):	Osteochondral fracture fragment (partial)
Stage III (C):	Osteochondral fracture fragment (detached)
Stage IV (D):	Osteochondral fracture fragment (displaced)



### TREATMENT

An podiatric surgeon should be consulted for treatment of talar dome lesions because of the high functional demands of the talar dome and the potential for complications. Stage I, II, and III medial lesions can usually be treated nonsurgically with six weeks in a nonweight-bearing cast. Adequate reduction and immobilization are crucial for fracture healing and to avoid avascular necrosis of the fracture fragment.

Patients with stage III lateral lesions, stage IV lesions, and persistent symptoms are generally treated surgically. Treatment options for fragment excision range from arthroscopy with or without subchondral bone drilling to open reduction internal fixation.